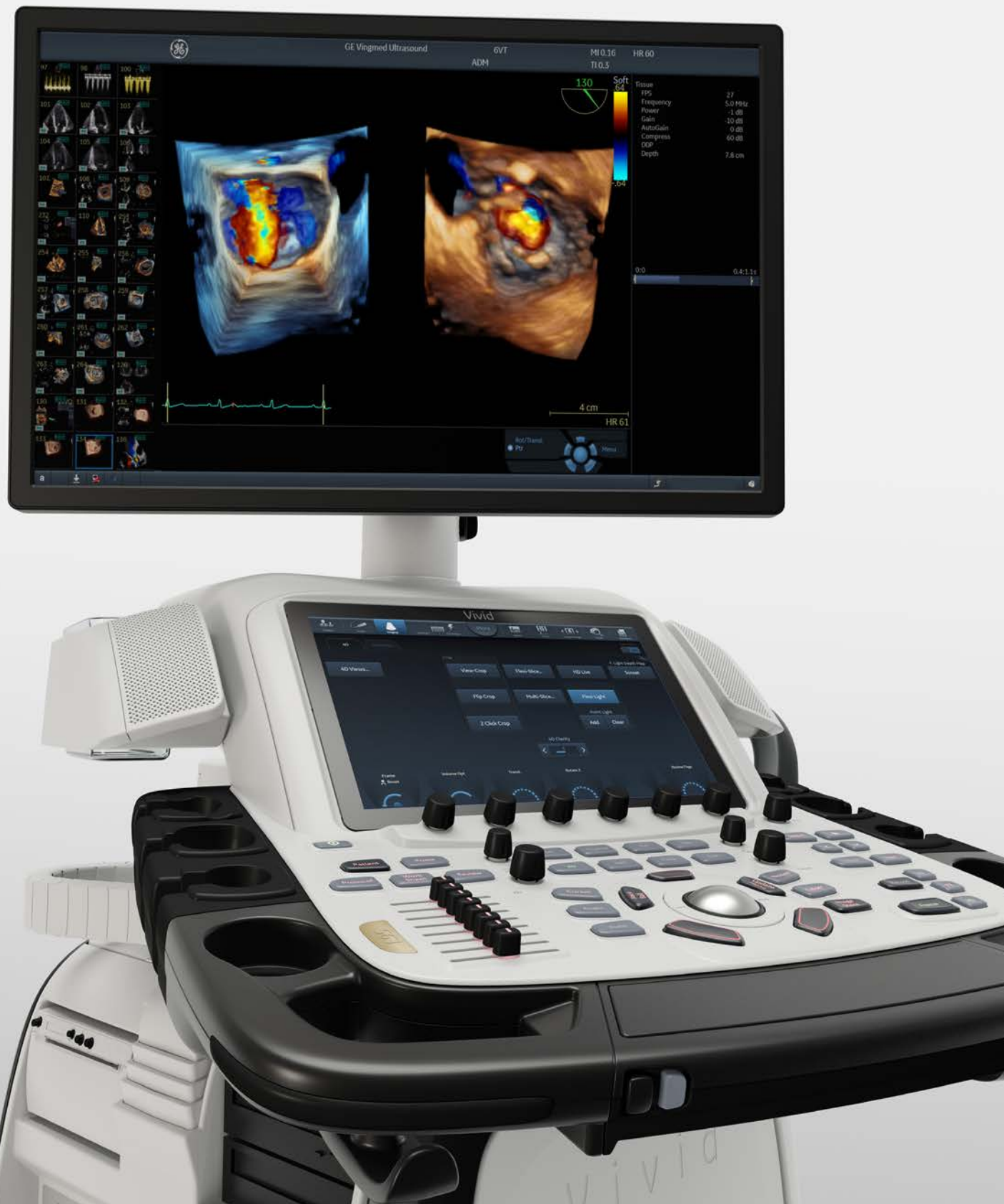



Navigating unreachable hearts

Redefining accessibility and safety with the 9VT-D mini 3D TEE probe

There is growing evidence that the world's first mini 3D TEE probe is expanding possibilities in the structural heart space,^{1,2} enabling more opportunities to reach complex and challenging patients. The latest example comes from Jyothy Puthumana, M.D., Director of Interventional Echocardiology at Northwestern Medicine's Bluhm Cardiovascular Institute.

Recognized among the top ten best cardiology, heart & vascular surgery programs in the United States, the Bluhm Institute is a leading destination for specialized heart care. Director of Interventional Echocardiology, Jyothy Puthumana, M.D., celebrates his 20th anniversary at the Institute next year. Over the years, he's welcomed innovation and change, exploring new ways to keep up with the increasing demand for structural heart interventions.

Dr. Puthumana and his team perform all the preprocedural TEEs for patients and trial participants who need structural heart interventions. Intraoperatively, he works very closely with interventionalists, cardiac surgeons and electrophysiologists to assist in TEE, valve replacement on the mitral or tricuspid side, and other structural interventions, including ASD closures and left atrial appendage occlusion procedures. Northwestern Medicine performs more than 70 TEER procedures a year.

Dr. Puthumana recently experienced GE HealthCare's 9VT-D mini 3D TEE probe powered by the Vivid™ E95 Ultra Edition cardiovascular ultrasound system. With a 57% smaller tip volume than the 6VT-D conventional adult TEE probe,³ the compact probe provided an imaging solution to evaluate and guide a TEER procedure in an elderly patient who could not tolerate an adult probe.

We asked Dr. Puthumana to share his initial impressions about the 9VT-D mini 3D TEE probe, along with some insights on the potential impact for the future.

Can you take us back and describe your evolving role in structural heart interventions during your time at the Bluhm Institute?

Dr. Puthumana: *During my first ten years, I got a lot of experience in the operating room because the echocardiologists would be there pre and post for every surgery case, mostly for valve repair, but also for valve replacements and later as TAVR started. As a result, we felt like we fit right in when nonsurgical valve repair/replacements came into foray.*

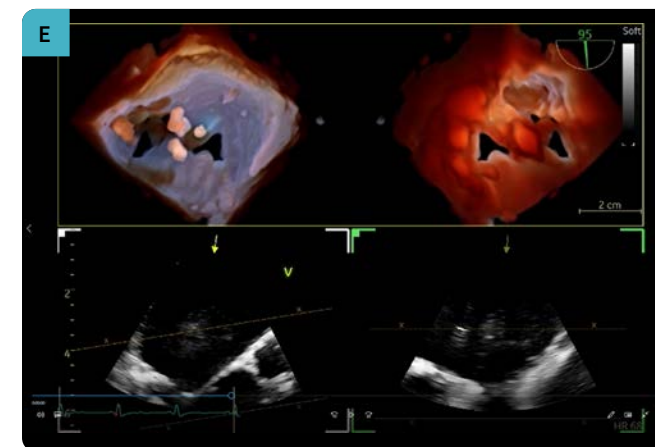
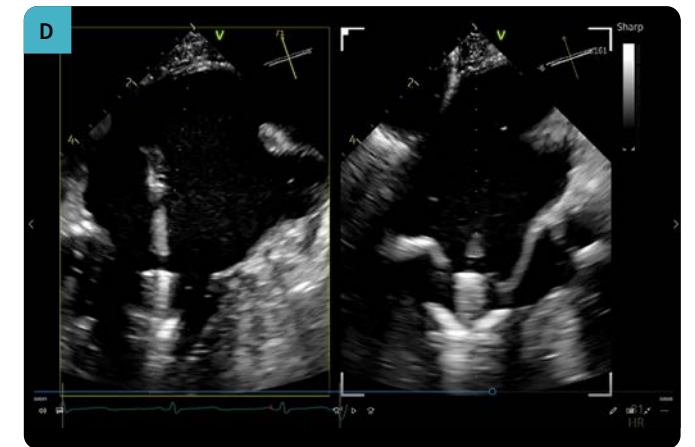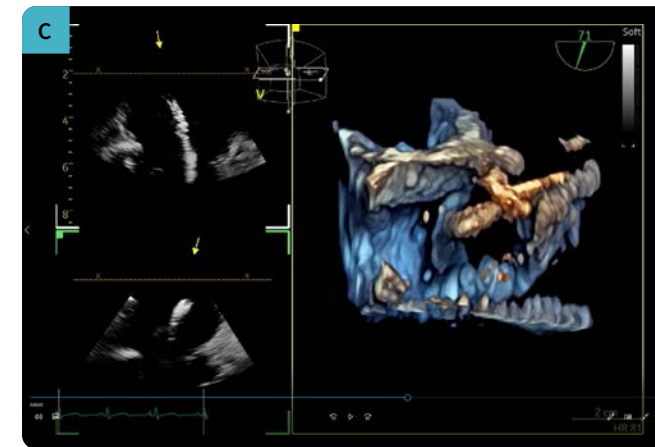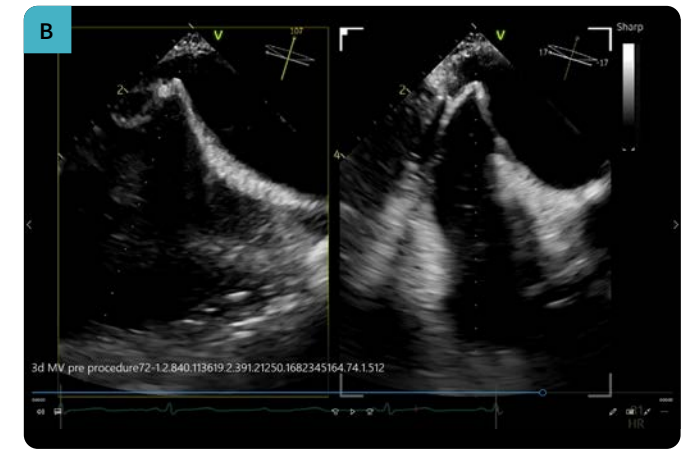
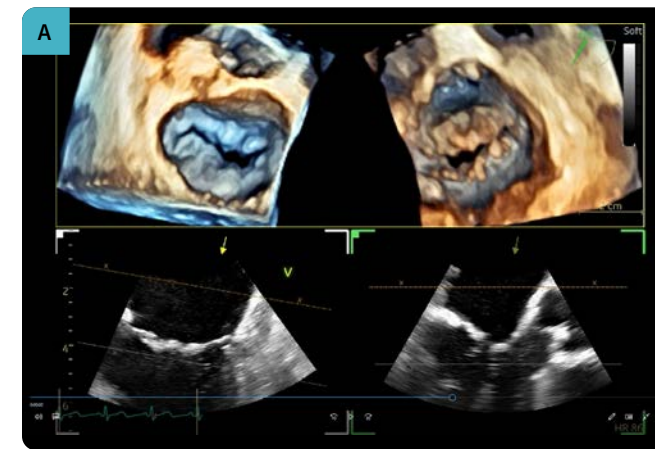
We used to perform the TEEs for TAVR assessment and intraoperative guidance during the initial PARTNER trials. When TEER came into existence as the first of the nonsurgical mitral valve procedures as part of two trials, we were well-positioned because of our experience from the OR. Here was a procedure that was very attractive and interesting to us, and it felt like we were making a difference in both preprocedural assessment and intraoperative guidance. We started off with the mitral valve transcatheter edge-to-edge repair and we were lucky to get involved in tricuspid trials early on, starting in 2015. We have been able

to gain a lot of tricuspid experience because patients are being referred for these trials at Northwestern Medicine.

You've recently evaluated the new 9VT-D mini 3D TEE probe. Can you tell us more about the specific case, including the patient history and procedure?

Dr. Puthumana: *We had an elderly, frail patient, who had severe mitral regurgitation, in addition to a host of other medical issues. Her main problem was Scleroderma related esophageal stricture. So even for a diagnostic study, her esophageal size was too small to accommodate a regular TEE probe. She underwent two esophageal dilations, which could be safely and maximally dilated up to only 14 to 15 millimeters in diameter at the largest location. We were lucky we had access to the mini 3D TEE probe because she needed imaging to both evaluate and to guide a potential TEER procedure.*

“ *I see this as moving the field forward by having a device that will potentially cause less irritation, injury to the esophagus, but at the same time provide imaging that is comparable and adequate for a successful completion of the procedure. I think the size of the probe is going to be a big part of this entire discussion.*



- A) Preprocedural 4D TEE using the 9VT-D mini 3D TEE probe of the mitral valve.
- B) Biplane image from the 9VT-D mini 3D TEE probe of transseptal puncture.
- C) 4D TEE image with the 9VT-D mini 3D TEE probe, manipulation of clip before crossing the mitral valve.
- D) Biplane image of clip moving past the mitral valve into the left ventricle.
- E) Dual crop image with Flexi-Light using the 9VT-D mini 3D TEE probe, post successful mitral valve TEER deployment.

What were your initial impressions of the 9VT-D mini 3D TEE probe?

Dr. Puthumana: This was the perfect probe that allowed us imaging from a biplane standpoint, imaging from a 3D standpoint and all the usual tools that we use in our routine mitral TEER procedures for transeptal puncture, navigating in the left atrium, navigating above the valve, orientation of the device arms, adequate leaflet grasp and capture, assessment of success of the procedure and finally safe removal of catheters and guide, post procedure.

Without the mini 3D TEE probe, I don't think our patient would have been able to get this procedure. The only other potential option could have been ICE. While we have experience with ICE on the tricuspid side, we don't have a lot of experience with ICE on the mitral side. I think this was the perfect option that aligned our existing expertise with TEE imaging with 3D in the TEER space, but with a probe that was appropriate for her esophageal size.

Intraprocedural TEE plays an essential role in guiding TEER. How would you describe the imaging capabilities?

Dr. Puthumana: We went into the case thinking that we would predominantly use the biplane feature to help us with positioning and capture. But once we were in the procedure, we used the three-dimensional multiplane cropping tool, FlexiSlice. We were able to get the 3D image of the mitral valve, device, and the clip, but also the commissure and the orthogonal view to help us both in terms of positioning and visualization of the entire device.

We felt that the imaging that we obtained using this probe was comparable to what we've been able to achieve in our prior cases utilizing a conventional adult TEE probe with 3D and multiplanar imaging. Along with our interventionalists, we felt confident that leaflet capture and insertion was good and that we obtained our outcome with the lowest risk possible.

“ Without the mini 3D TEE probe, I don't think our patient would have been able to get this procedure. ”

What surprised you the most about the 9VT-D mini 3D TEE probe?

Dr. Puthumana: Our patient was very frail and her esophagus had been dilated multiple times so we were apprehensive and conscious that we could potentially make her esophagus worse from probe manipulation. We were pleasantly surprised at how smooth the movement was within her esophagus and our ability to maneuver the probe without feeling any restriction or difficulty advancing or retracting.

Do you think the 9VT-D mini 3D TEE probe can increase access of TEE-guided procedures to this subset of patients who have esophageal strictures?

Dr. Puthumana: We definitely needed a probe that enables us to get comparable images, but does not risk injury to the esophagus, which would then compromise the benefit we get from taking care of the regurgitation.

I see this as moving the field forward by having a device that will potentially cause less irritation, injury to the esophagus, but at the same time provide imaging that is comparable and adequate for a successful completion of the procedure. I think the size of the probe is going to be a big part of this entire discussion.

What other types of patients would benefit from having a much smaller 9VT-D mini 3D TEE probe?

Dr. Puthumana: I suspect that from a mitral and tricuspid structural standpoint, the TEER space is going to be the first area where there is going to be a rapid expansion in the eligibility of the number of patients coming in. And most of the patients who are eligible for TEER at present are quite frail and tend to have multiple issues, including esophageal issues. You also have patients who are coming in with bleeding issues, liver issues. A lot of these patients have hepatic congestion, cirrhosis and so forth and are already at high risk for esophageal injury. I think this probe can be considered as an option for these high-risk and frail patients who are currently coming in for these procedures and for other tricuspid valve related procedures as more devices get approved for clinical use in the future.

What are your thoughts about reducing esophageal injuries in longer TEE-guided procedures?

Dr. Puthumana: As the number of structural procedures that need TEE guidance has increased, people are paying more attention to the risks associated with structural imaging.

There have been several big studies looking into these risks of esophageal injury/irritation, and we have more knowledge in this arena than we did five years ago.

I think all of us in the structural imaging arena were both stumped and concerned when one study reported that 86% of patients had a new injury noted on EGD post procedure, with complex lesions noted in close to 40% of patients. These were patients predominately undergoing mitral valve structural interventions, with a few appendage closures, and tricuspid devices.^{4,5} I think we are now humbled by these studies that show structural imaging is not benign as we had presumed, and we are treating the

sickest of sick patients. I think there's more awareness about how we can make imaging safer, make it shorter, and still get all the information we need for a successful result.

Do you think the 9VT-D mini 3D TEE probe may reduce the need for general anesthesia in the future? How could that benefit patients?

Dr. Puthumana: It would be huge, as we've seen with the TAVR space and how it had a big impact on length of stay and other complications associated with general anesthesia. Obviously, the structural field is moving towards more and more procedures that can be done with as little general anesthesia as possible.

I think it would be a huge advancement and would benefit our older, more frail patients. Hopefully that will be tested once the probe becomes more widely available and we perform a multicentric study with this approach starting off with procedures that have a very predictable time for procedure. (Example: straightforward mitral lesions at the A2-P2 location with no other procedural challenges expected.) It would be very exciting if we could push the field that way. I hope that's where things are headed, in the future of structural imaging. ■



Jyothy Puthumana, M.D., is Director of Interventional Echocardiology at Northwestern Medicine's Bluhm Cardiovascular Institute. He is also Medical Director of the Martha and Richard Melman Family Bicuspid Aortic Valve Program at Northwestern Memorial Hospital. Dr. Puthumana's top areas of expertise include all valvular heart disease with a special expertise in bicuspid aortic valve disease and structural imaging. He has co-authored more than 40 peer-reviewed articles and is committed to research, participating in many clinical trials.

- 1 Hascoët S, Peyre M, Hadeed K, Alacoque X, Chausseray G, Fesseau R, Amadiou R, Léobon B, Berthomieu L, Dulac Y, Acar P. Safety and efficiency of the new micro-multiplane transoesophageal probe in paediatric cardiology. Arch Cardiovasc Dis. 2014 Jun-Jul;107(6-7):361-70. doi: 10.1016/j.acvd.2014.05.001. Epub 2014 Jul 1. PMID: 24996565
- 2 Sanchis L, Regueiro A, Cepas-Guillen P, Sitges M, Freixa X. First experience of left atrial appendage occlusion using a 3D mini transoesophageal echocardiographic probe with conscious sedation. EuroIntervention. 2023 Jan.; doi: 10.4244/EIJ-D-22-00921
- 3 Volume of the TEE probe tip compared to standard adult probe 6VT-D Vivid probe. DOC2636172
- 4 Freitas-Ferraz AB, Bernier M, Vaillancourt R, et al., J. Safety of Transesophageal Echocardiography to Guide Structural Cardiac Interventions. J Am Coll Cardiol. 2020 Jun 30;75(25):3164-3173. doi: 10.1016/j.jacc.2020.04.069. PMID: 32586591
- 5 Aragam JR, Almarzooq ZI. Transesophageal Echocardiography in Structural Heart Interventions: Is it Time to Rethink Our Approach? J Am Coll Cardiol. 2020 Jun 30;75(25):3174-3176. doi: 10.1016/j.jacc.2020.05.018. PMID: 32586592

Doctors are paid consultants for GEHC and were compensated for participation in this article. The statements described here are based on their own opinions and on results that were achieved in their unique setting. Since there is no "typical" hospital and many variables exist, i.e. hospital size, case mix, etc., there can be no guarantee that other customers will achieve the same results.

JB26292XX